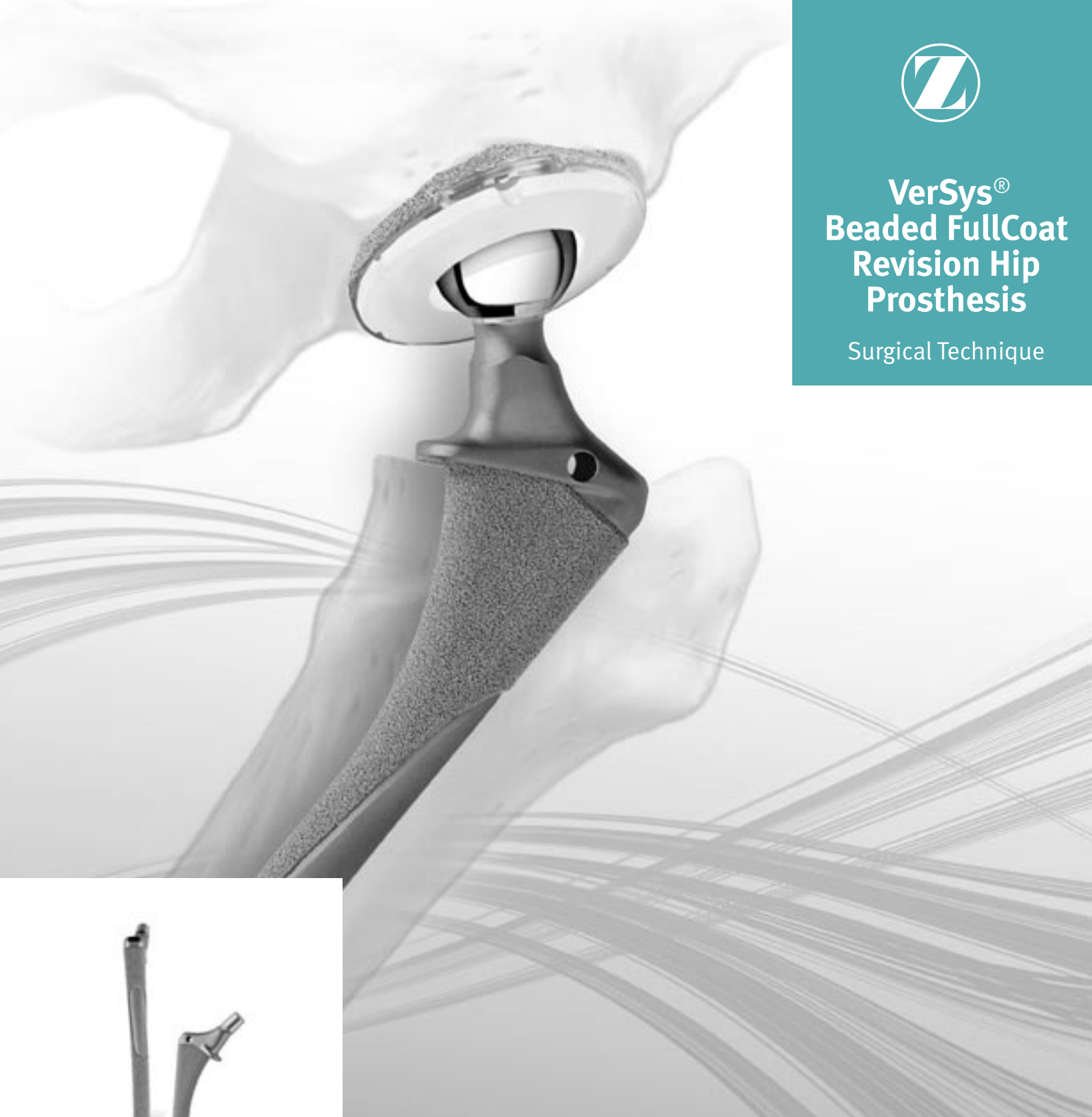



VerSys® Beaded FullCoat Revision Hip Prosthesis

Surgical Technique



Proven philosophy with multiple options

**VerSys® Beaded FullCoat
Revision Hip Prosthesis
Surgical Technique****Table of Contents**

Preoperative Planning	1
Objectives of Preoperative Planning	1
Bone Deficiency Classification	1
Component Selection to Address Bone Loss	6
Determination of Leg Length	6
Determination of Femoral Offset and Abductor Muscle Tension	7
Templating	7
Surgical Technique	10
Surgical Approach Factors	10
Determination of Intraoperative Leg Length	15
Component Removal	15
Osteotomy of the Femoral Neck	17
Intramedullary Reaming	18
Rasping	21
Medial Bone Resection for Calcar* Stem	24
Trial Reduction	25
Implantation	26
Stem Insertion	26
Wound Closure	28
Postoperative Management	28

Preoperative Planning

Preoperative planning is of critical importance in femoral revision surgery. It helps determine the technique for removal of the existing implant, the size and location of bone deficiencies, and the type and approximate size of femoral implant required to reconstruct the femur. As in any revision procedure, the specific technique will vary depending on the approach. When revising a femoral component, the surgeon must decide on the best surgical approach and method of removing the femoral prosthesis that will provide adequate exposure while minimizing additional bone loss.

Objectives of Preoperative Planning

The objectives of preoperative planning include:

1. Determining technical requirements for removal of the implant.
2. Assessing amount of bone loss to:
 - Select type(s) of implant(s) appropriate to reconstruct the femur.
 - Determine any special needs such as allograft or adjunctive fixation (cables, plates, etc.).
3. Obtaining the anticipated component size necessary to provide structural stability.
4. Establishing parameters of joint kinematic restoration that include:
 - Determination of leg length.
 - Restoration of offset for abductor muscle tensioning.
5. Assessing the acetabulum to determine if any acetabular reconstruction is needed, and consider the potential effect of the acetabular reconstruction on the femoral side.

Bone Deficiency Classification

There are a number of femoral bone defect classification systems using various methods with a range of complexity. The following classification systems allow femoral bone loss to be placed in easy-to-recognize categories based on radiographic identification. This will assist the surgeon in preoperative planning and intraoperative reconstruction; however, the revision strategy may change significantly based on other factors or intraoperative findings.

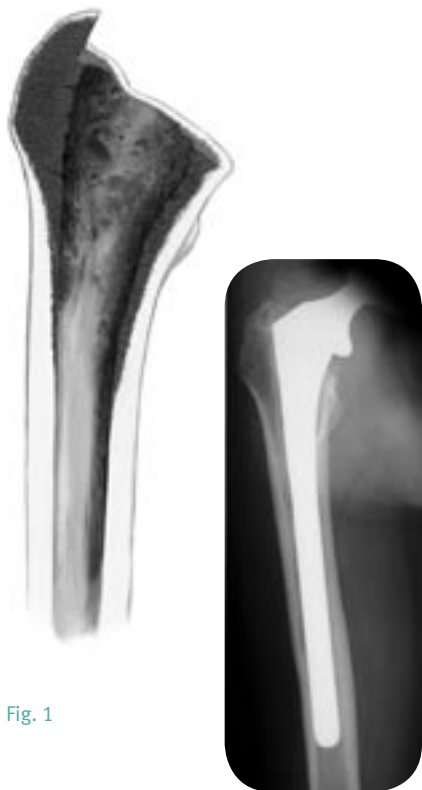Modified AAOS Femoral Defect Classification System*

Fig. 1

Type I Femoral Deficiency

- No significant bone loss

Type I femoral bone deficiencies (Fig. 1) are similar to a primary total hip with some minor bone defects. Type I deficiencies have the least amount of bone loss, and provide good bone for structural support and implant fixation.

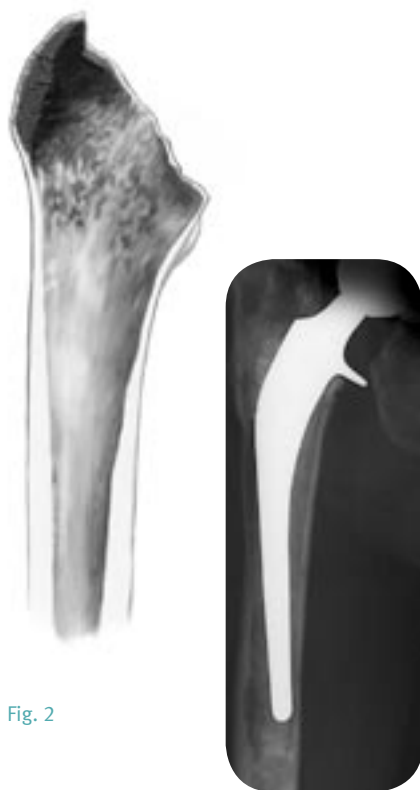

Fig. 2

Type II Femoral Deficiency

- Contained “ballooning” cavitory bone loss with thinning of cortices

Type II femoral bone deficiencies (Fig. 2) represent more bone loss in the proximal femur that is contained within thinning cortices. Type II deficiencies provide less proximal femoral structural support, particularly in controlling rotation.

* Saleh KJ, Gross AF, Gafni A, et al. Radiographic classification for failed hip arthroplasty. 53rd Annual Meeting, Canadian Orthopaedic Association, June 1998, Ottawa, Ontario.

Modified AAOS Femoral Defect Classification System*

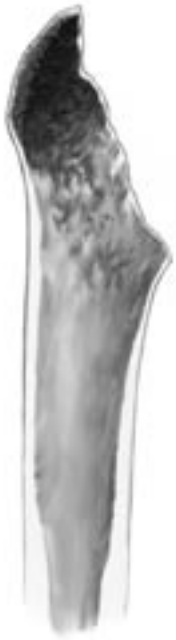

Fig. 3

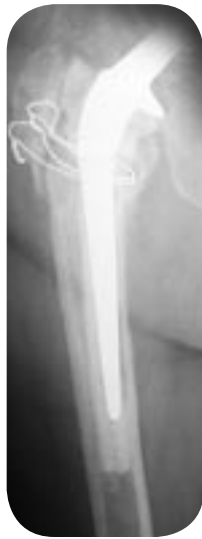
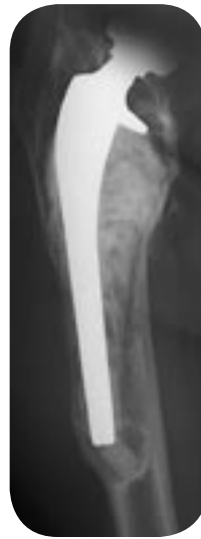
Fig. 4



Type III Femoral Deficiency

- Uncontained segmental bone loss less than 5cm in length, extending to the level of the lesser trochanter

Type III femoral bone deficiencies (Fig. 3) are characterized by more extensive bone loss that is uncontained in the proximal femur. Segmental bone loss does not provide for resistance to axial or rotational forces.

Type IV Femoral Deficiency

- Uncontained segmental bone loss greater than 5cm in length, extending into the diaphysis

Type IV femoral bone deficiencies (Fig. 4) demonstrate severe proximal femoral bone loss with involvement of the diaphysis. There is no supportive proximal femoral bone and the diaphyseal structural support is compromised or minimal.

* Saleh KJ, Gross AF, Gafni A, et al. Radiographic classification for failed hip arthroplasty. 53rd Annual Meeting, Canadian Orthopaedic Association, June 1998, Ottawa, Ontario.

Paprosky Femoral Defect Classification System**

Fig. 5

Type I Defect

- No significant bone loss

Type I defects (Fig. 5) are similar to a primary total hip with very minor loss of calcar and A/P bone. Metaphyseal and diaphyseal bone is intact, providing good bone for structural support and implant fixation.



Fig. 6

Type II Defect

- Metaphyseal bone loss only

Type II defects (Fig. 6) involve bone loss in the metaphysis only, with intact diaphyseal bone. The calcar is completely eroded, and the metaphysis shows A/P loss of cancellous bone. Type II defects provide minimal proximal femoral support.

** Paprosky WG, Burnett SJ. Assessment and classification of bone stock deficiency in revision total hip arthroplasty. *Am J Orthop.* August 2002;31(8):459-464.

Paprosky Femoral Defect Classification System**

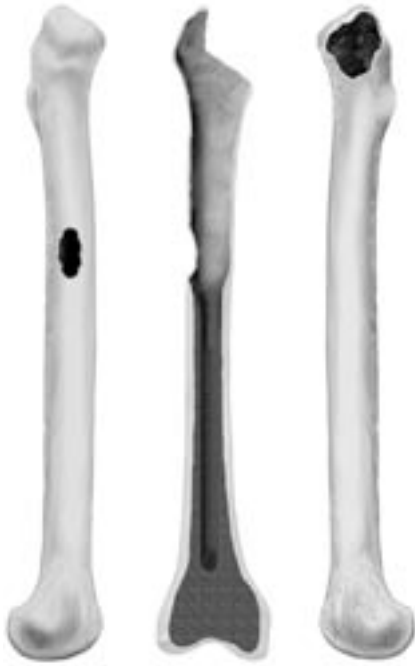

Fig. 7

Type IIIa Defect

- Metaphyseal bone loss extending to the diaphyseal junction

Type IIIa defects (Fig. 7) involve significant metaphyseal bone loss that extends to the junction between the metaphysis and the diaphysis. Sufficient bone stock remains for a 4cm-5cm scratch fit near the isthmus.

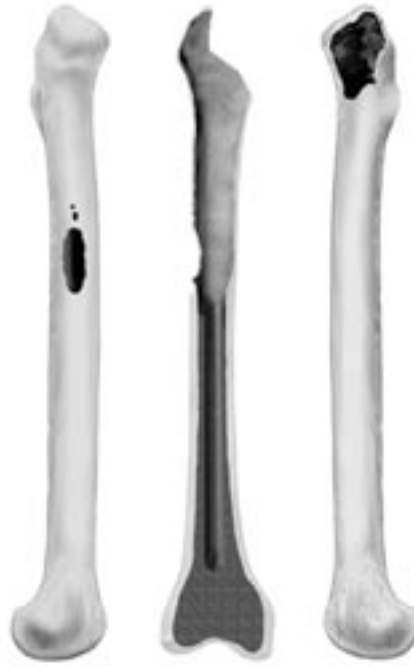

Fig. 8

Type IIIb Defect

- Metaphyseal bone loss extending slightly below the diaphyseal junction

Type IIIb defects (Fig. 8) involve significant metaphyseal bone loss that extends below the junction between the metaphysis and the diaphysis. There is insufficient bone stock near the isthmus, requiring diaphyseal fixation beyond the isthmus. Grafting may also be necessary.

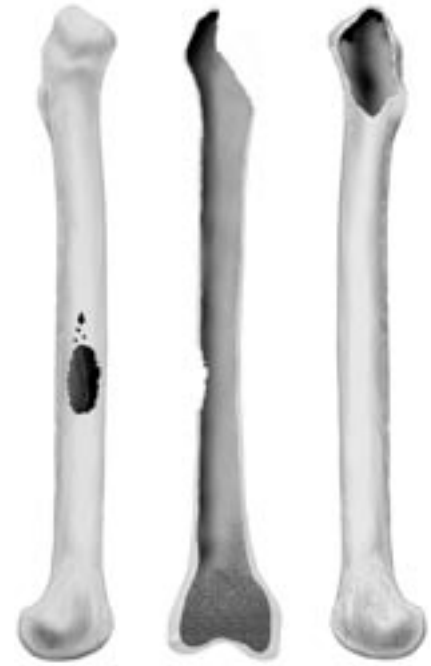

Fig. 9

Type IV Defect

- Extensive metaphyseal and diaphyseal bone loss

Type IV defects (Fig. 9) involve severe bone loss in both the metaphysis and diaphysis. The cortices are thin and the canal is widened. Neither proximal nor distal fixation is possible and the isthmus provides no support. Impaction grafting is required.

** Paprosky WG, Burnett SJ. Assessment and classification of bone stock deficiency in revision total hip arthroplasty. *Am J Orthop.* August 2002;31(8):459-464.

Component Selection to Address Bone Loss

To select the appropriate type of implant in femoral revision surgery, a number of factors must be considered. Reconstructing the femur based on the amount of femoral bone loss and the status of the remaining bone is important in determining the appropriate prosthesis. The *VerSys* Beaded FullCoat Revision Hip Prosthesis can address a wide variety of femoral revision needs. The system is a logical choice for Type II and Type III femoral bone deficiencies, and can also be used with some Type I and some Type IV deficiencies. The choice of implant will depend on the individual patient and the surgeon's fixation preference.

Warning: Where there is loss of or insufficient femoral bone stock, bone grafting, or other adjunctive reinforcement procedures are advisable to provide proximal support to the stem. This is because, without proximal support, the stem is vulnerable to fracture. In cases where proximal support cannot be achieved, an alternative surgical option should be considered.

Determination of Leg Length

Preoperative determination of leg length is essential for the restoration of the appropriate leg length during surgery. Correction of leg length discrepancy is usually necessary because of bone and soft tissue changes resulting from the failed prosthesis.

Anterior/posterior (A/P) pelvic radiographs often provide enough detail of leg length inequality to proceed with surgery. If more information is needed, a scanogram may be helpful. From the clinical examination and radiographic information, the needed correction, if any, can be determined.

If leg length is to be maintained or minimally increased, it is usually possible to perform the operation successfully without osteotomy of the greater trochanter, unless extensive exposure of the acetabulum is necessary. However, if there is some major anatomic abnormality, osteotomy of the greater trochanter may be helpful for acetabular revision. In some cases, an extended trochanteric osteotomy (ETO) (Fig. 10), may be appropriate. This technique facilitates exposure of the femur and acetabulum. It is an extremely versatile procedure that can be performed at any time during the revision procedure.

In the unusual situation, a sub-trochanteric osteotomy, or osteotomy and advancement of the greater trochanter are necessary. Without one of these techniques, the abductors will be lax postoperatively, and the risk of dislocation will be high. Also, gait will be compromised by the laxity of the abductors.

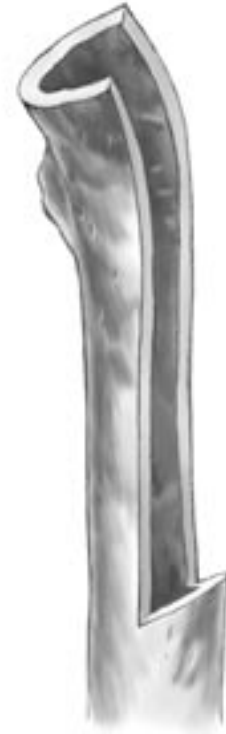

Fig. 10

Determination of Femoral Offset and Abductor Muscle Tension

After determining the desired leg length requirements, abductor muscle tensioning through femoral offset must be considered. Restoring abductor tension places the abductor muscles at their optimal mechanical advantage, and results in improved function with less chance of dislocation and limp.

If an osteotomy or extended osteotomy of the greater trochanter is performed, the abductor tension can be established independently of any other variable simply by adjusting the site of reattachment of the osteotomized bone to the femur. In this case, matching the patient's offset as it relates to the muscle tension and hip stability is less important.

In most cases, if the greater trochanter is not osteotomized, abductor length will generally be correct when leg length is re-established. There are uncommon, but important exceptions to this. If the patient has a very large offset between the femoral head center of rotation and the line that bisects the medullary canal, the insertion of a femoral component with a lesser offset will, in effect, medialize the femoral shaft. To the extent that this occurs, laxity in the abductors will result and the risk of dislocation will increase. The contralateral hip, if normal, is a useful guide in adjusting leg length and offset on the operative side.

It may not be possible to completely restore offset in patients with an unusually large offset or in patients with a severe varus deformity. In such cases, the tension in the abductors can be increased by lengthening the limb. This is especially valuable when the involved hip is shorter. If this option is not advisable and the offset achieved at surgery by using the longest head/neck component possible is inadequate, it may be necessary to advance the greater trochanter to eliminate the laxity in the abductor muscles. Another option is to use a lateralized polyethylene liner in the acetabular component. Intraoperative assessment of hip stability will help in making this decision.

Using the *VerSys* Beaded FullCoat Revision Templates on the preoperative x-ray film allows the surgeon to estimate the amount of offset needed for the new femoral component.

Templating

The objective in templating the *VerSys* Beaded FullCoat Revision Femoral Component is to determine the type, size, length, and offset of the femoral component. Templating is also important in choosing the acetabular component if it is also being revised. Acetabular preoperative planning is beyond the scope of this document, but must be considered in conjunction with the use of the *VerSys* Beaded FullCoat Revision Femoral Prosthesis.

It is important during preoperative planning to provide sufficient radiographic visualization to determine the full extent of the femoral deformity. Preoperative planning for the insertion of the *VerSys* Beaded FullCoat Revision Femoral Component requires at least three views of the involved femur: an A/P view of the pelvis centered on the pubis symphysis, a full length A/P view of the involved side with the femur slightly internally rotated, and a Lowenstein lateral view on an 11- x 17-inch cassette. The lateral radiograph will aid in determining the amount of anterior femoral bow and whether to use a straight or a bowed stem. This compensates for naturally occurring femoral anteversion, and provides a more accurate representation of the true anteroposterior dimension of the metaphysis. Note, however, that the stem may be loose and retroverted. Also, an internally rotated film may be difficult to obtain because of an external rotation contracture. In these cases, it may be helpful to obtain a posterior/ anterior radiograph with the patient prone, and a bolster placed beneath the opposite hip to internally rotate the affected hip.

When templating, magnification of the femur will vary depending on the distance from the x-ray source to the film, and the distance from the patient to the film. The *VerSys* Beaded FullCoat Revision Templates use 20 percent magnification, which is near the average magnification on most clinical x-ray films. Large patients and obese patients may have magnification greater than 20 percent because their osseous structures are farther away from the surface of the film. Likewise, smaller patients may have magnification less than 20 percent. If necessary, to better determine the magnification of any x-ray film, use a standardized marker at the level of the femur. (Templates of other magnification can be obtained as a special order by contacting your Zimmer Sales Representative.)

Mark the hip center on the x-ray to facilitate determination of neck length, offset, and level of seating of the femoral component.

The *VerSys* Hip System includes six head diameters, allowing the surgeon to choose the most appropriate one. In most patients with average-size acetabula, a 32mm or 36mm diameter femoral head is preferable for revision arthroplasty. These femoral heads permit the use of an acetabular component with an outside diameter small enough that it can be completely seated in bone while permitting the use of Longevity® Highly Crosslinked Polyethylene Liners of sufficient thickness. In special circumstances, such as the treatment of small patients, and in patients with congenital hip dysplasia and small acetabular volume, it may be preferable to use a 22mm, 26mm, or 28mm head diameter to allow the use of a small acetabular component.

First, select the femoral template. The *VerSys* Beaded FullCoat Revision Femoral Components are currently available in 8-inch (7.5-inch for straight stems) and 10-inch stem lengths, and in a variety of configurations, including straight, anterior bowed, and calcar. (Note: Please refer to the chart below for specific product data.)

VerSys Beaded FullCoat Revision Sizing Options

	Length	Number of Sizes	Size Range	Sizing Increments
Straight Stems	7.5 inch	8	12mm-22.5mm	1.5mm
	10 inch	6	15mm-22.5mm	1.5mm
	7.5 inch Calcar (+10mm)	7	13.5mm-22.5mm	1.5mm
	7.5 inch Calcar (+20mm)	6	15mm-22.5mm	1.5mm
Anterior Bowed Stems	8 inch	7 (left & right)	13.5mm-22.5mm	1.5mm
	10 inch	7 (left & right)	13.5mm-22.5mm	1.5mm
	10 inch Calcar (+10mm)	7 (left & right)	13.5mm-22.5mm	1.5mm
	10 inch Calcar (+20mm)	6 (left & right)	15mm-22.5mm	1.5mm

The Beaded FullCoat Revision Bowed Stems have 16 degrees of anteversion built into the stem (Fig. 11). This is accomplished by anteverting the body 8 degrees relative to the distal stem, and anteverting the neck an additional 8 degrees relative to the body. This permits contact with the best available bone in the canal while allowing for more anatomic stem position, particularly in the bowed stems.

The femoral templates show the neck length and offset for each of the head/neck combinations (-3.5mm to +10.5mm, depending on head diameter). Skirts are included on +7mm and +10.5mm heads. The template allows simultaneous assessment of the femoral component fit in the femoral canal, and the effect of head/neck length on limb and femoral offset.

Selection of the stem configuration is determined in part by the femoral bone deficiency as assessed on the A/P radiograph. When there is medial segmental femoral bone loss, either a large metaphyseal or calcar stem can be used, depending on the amount of bone loss.

Determination of the size of the implant to insert requires assessment of the canal size on the A/P film, the metaphyseal size on the A/P film, and the canal size and degree of femoral canal bowing on the lateral film. To determine the approximate size of the femoral stem to be used, superimpose the templates on the isthmus. The stem should fill, or nearly fill, the medullary canal in the isthmus area on the A/P x-ray film. To provide for adequate stability, the stem length should be sufficient to engage at least 5cm of the femoral canal. Then assess this template relative to the fit of the body in the metaphyseal area. The medial portion of the body of the component should fill the metaphysis of the proximal part of the femur as fully as is compatible with the anatomic contours of that region. All Beaded FullCoat Revision Stems have revision offsets and large metaphyseal (LM) bodies.

Warning: In cases where there is loss of or insufficient femoral bone stock proximally, a calcar stem, additional bone graft, use of cortical strut allografts, or other adjunctive reinforcement procedures are needed to provide proximal support to the stem. It is important that the prosthesis not be distally fixed without proximal support.

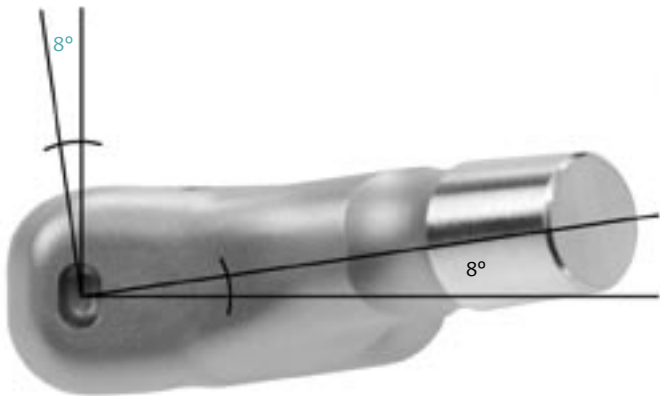


Fig. 11

Next, check the fit of the stem on the lateral x-ray film to assess fill and appropriate stem length while taking the anterior bow of the femur into consideration. If the A/P dimension of the isthmus (as seen on the lateral x-ray film) is greater than the mediolateral dimension shown on the A/P film, it may be advantageous to increase the size of the femoral canal to accommodate a stem that better fills the isthmus. Templating for the next larger size femoral component on the A/P film will determine the amount of cortical bone that needs to be removed by reaming. The cortical thickness of the walls must be great enough to permit reaming.

If a larger stem would provide a better fill of the isthmus, it is preferable to insert the larger stem. This can be accomplished by enlarging the isthmus in the M/L dimension with intramedullary reamers. When a larger size is chosen to better fill the isthmus on the lateral film, the A/P film must be re-evaluated to make sure that both the proximal and distal portions of the stem fit acceptably. Careful attention to this process helps the surgeon to implant a stem that will provide maximum stability and contact with the host bone. When in doubt, intraoperative A/P and lateral x-ray views of the femur with a provisional stem in place will help with final stem selection.

Surgical Technique

Note: The surgeon who performs any procedure is responsible for determining and utilizing the appropriate techniques for such procedures for each individual patient. Zimmer is not responsible for selection of the appropriate surgical technique to be utilized for an individual patient.

Surgical Approach Factors

When determining which surgical approach is appropriate for a specific revision patient, a number of factors must be considered. The two most important factors are: 1) the difficulty of component removal, and 2) the complexity of the femoral reconstruction. Other considerations include prior approaches and leg length discrepancies.

There are advantages and disadvantages with all approaches used in hip surgery. It is important that the surgeon be proficient with several different approaches to individualize the approach according to patient needs.

Direct lateral (transgluteal)¹, anterolateral, or posterior² approaches provide exposure for difficult revisions. In some cases, a trochanteric osteotomy may be needed. A transverse trochanteric osteotomy provides pelvic exposure and very good femoral exposure, but there is a high incidence of trochanteric nonunion and escape.^{3,4} A trochanteric slide provides better femoral exposure and, because the abductors and the vasti remain attached to the trochanter as a sling, there is less risk of trochanteric escape. If more pelvic exposure is required, a trochanteric slide can be converted to a transverse osteotomy by releasing the vasti.⁴⁻⁶

The extended trochanteric osteotomy (ETO) provides the best femoral exposure and may be used when difficulty in removing the femoral component is anticipated.^{4,6,7,8} The extended trochanteric osteotomy and the slide also provide adequate pelvic exposure for complex acetabular reconstruction, but neither provides as much pelvic exposure as the transverse trochanteric osteotomy which provides the best access to the ilium and the anterior and posterior columns.

Removal of a protruded acetabular cup is difficult. Use extreme caution if the cup is adjacent to pelvic vessels or viscera. Preoperative angiography, CT, or IVP may be required, and a transtrochanteric approach or intra-abdominal approach may be necessary. On the femoral side, cemented long stem or porous coated long stems are the most difficult to remove. To facilitate removal of these components, an extended trochanteric osteotomy may be performed. Also, if preferred, an extended femoral slot can be used to facilitate removal of the femoral component. The extended femoral slot can be used with either a posterior or modified lateral approach.

If a complex acetabular reconstruction is necessary because of loss of bone stock, the exposure should extend from the ilium to the ischium. This may require an extended posterior approach, and may also require a trochanteric osteotomy. Likewise, a complex femoral reconstruction may be accomplished more easily and without increased risk of fracture if a trochanteric approach is used.

Posterior Approach

Use a posterior approach as part of the trochanteric slide or the extended trochanteric osteotomy. It can also be used for a transverse osteotomy, although this is more commonly accomplished through a lateral approach. Make the skin incision parallel to the femoral shaft to just proximal to the tip of the greater trochanter. Then curve the incision posteriorly toward the posterior iliac spine. Incise the fascia lata to expose the greater trochanter, abductors, and vastus lateralis. With the hip in abduction and external rotation, identify the anterior border of the gluteus medius and retract it posteriorly. Perform an anterior capsulectomy. Identify the interval between the gluteus minimus and gluteus medius. Then place the hip in internal rotation and flexion.

Retract the posterior borders of the gluteus medius and gluteus minimus anteriorly, and identify the external rotators. The silver-white tendon of the piriformis forms the most superior part of the external rotators and serves as a landmark. Detach a flap from the greater trochanter. This flap should consist of the external rotators, beginning at the piriformis and extending distally to the quadratus femoris. The flap may also include the quadratus femoris. Mark the flap with a suture for later repair.

If more extensive posterior exposure is required, incise the distal part of the gluteus maximus tendon and mark it with a suture for later repair. The sciatic nerve can be identified at this point and is thereafter protected. Perform a posterior capsulectomy and dislocate the hip posteriorly and anteriorly. This may be enough exposure but, if more is required, proceed to either a trochanteric slide or an extended trochanteric osteotomy.

Note: If planning to implant the prosthesis through the posterior approach without trochanteric osteotomy, it is important to use a high speed burr to remove overhanging bone on the greater trochanter, so that there will be a straight, unobstructed path down the femoral medullary canal.

Both the trochanteric slide and the extended osteotomy involve developing the interval between the vastus lateralis and the posterior septum. Reflect the vastus lateralis anteriorly, but maintain its attachment to the vastus lateralis ridge in continuity with the greater trochanter. This anterior reflection should not exceed 1cm as it is important to leave the proximal fragment vascularized.

Trochanteric Slide

For the trochanteric slide, use an oscillating saw or osteotome to perform the osteotomy from posterior to anterior in the sagittal plane. The osteotomy cut should exit just distal to the vastus lateralis ridge. This will leave the trochanteric fragment enclosed in a sling of muscle consisting of the abductors proximally and the vastus lateralis distally (Figs. 12 & 13). This allows for stable reattachment and decreases the potential for trochanteric escape.

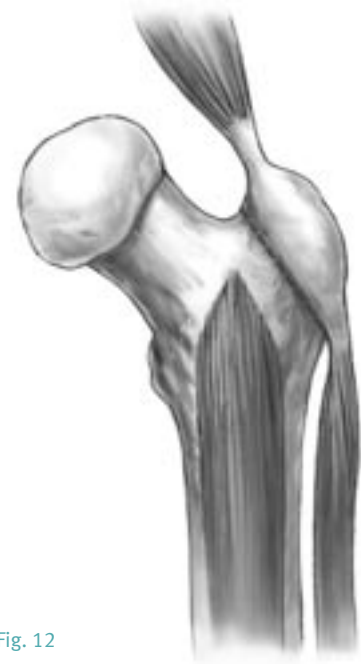

Fig. 12

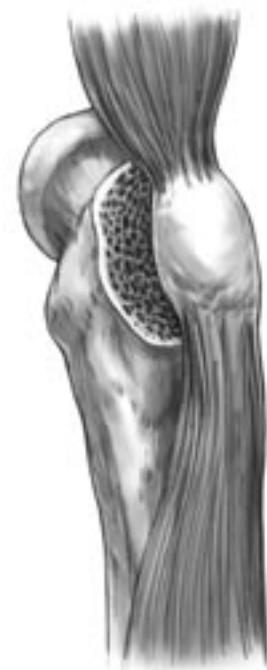

Fig. 13

If desired, the trochanteric fragment can be made thick to include the gluteus medius and minimus. To accomplish this, angle the osteotomy anteromedially. Alternatively, the osteotomy can include the gluteus medius only, leaving the gluteus minimus attached to the femur. This will create a thinner fragment. Then, after making the osteotomy cut, dissect the gluteus minimus off the femur. It can be repaired later along with the external rotators. Having the gluteus minimus detached from the trochanteric fragment allows easier and more stable reattachment of the trochanteric fragment. If left attached to the trochanteric fragment, the gluteus minimus tethers the fragment anteriorly.

Retract the trochanteric fragment and its attached muscles anteriorly. Then use a large self-retaining retractor to dislocate the hip posteriorly in adduction and internal rotation.

To reattach the greater trochanter, use two cerclage wires through the lesser trochanter, or through the medial femoral cortex and the greater trochanter. If the trochanter is fragile, place the wires around the trochanter rather than through the drill holes. Often, wire mesh or a trochanteric clamp will be necessary. Then repair the external rotators and the gluteus minimus, and suture the vastus lateralis back to the septum (Figs. 14 & 15).

Extended Trochanteric Osteotomy for an extended trochanteric osteotomy, the osteotomized fragment is much thicker, includes the entire trochanter, and extends into the diaphysis. The fragment includes the insertion of the gluteus medius and gluteus minimus, and involves approximately one-third of the diameter of the femur. The distal extent of the osteotomy depends on the length and fixation of the component to be removed and is determined from preoperative templating.

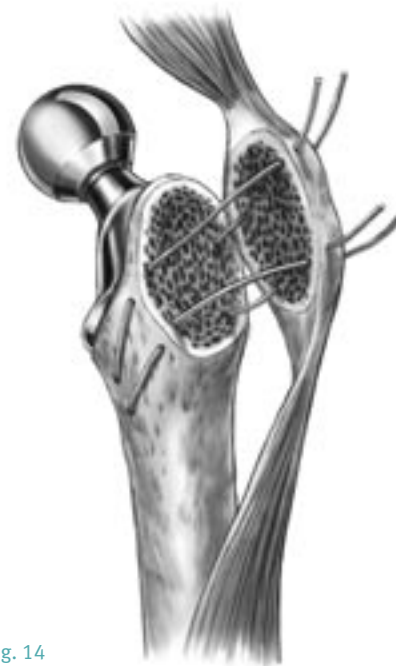


Fig. 14

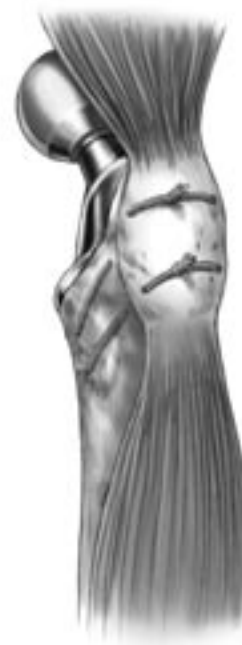

Fig. 15

Because the osteotomy involves one-third of the circumference of the femur, it is more easily performed after the hip has been dislocated and the femoral component removed. Typically, however, this is not possible because this approach is often being done to facilitate implant removal. In addition, if dislocation is difficult, the osteotomy should be done first.

An extended trochanteric osteotomy can be performed using a posterior approach, or an anterolateral approach. For the posterior approach, reflect the vastus lateralis off the septum, being careful to identify and cauterize perforating vessels. Limit the anterior reflection of the vasti muscles off the septum to about 1cm, or just enough to allow access for an oscillating saw or a high-speed burr. It is important to keep the muscle and the blood supply it brings attached to the long bony fragment.

With the hip in slight internal rotation, use an oscillating saw to perform the posterior limb of the osteotomy. Proximally, angle the saw blade medially to include all of the greater trochanter.

Continue the cut distally on the posterolateral femur, just anterior to the linea aspera. The osteotomy should not exceed one-third the diameter of the proximal femur. Keep the distal horizontal end of the osteotomy rounded. If the femoral implant is small, it may be possible to make both the posterior and anterior cuts by passing the blade from posterior to anterior across the canal. If this is not possible, then use a narrow osteotome to weaken the anterior cortex after the posterior cut is made. Make multiple perforations through the muscle anteriorly without stripping it. This will keep the vastus lateralis attached, and the fragment vascularized. To avoid fracturing the greater trochanter, release the capsule anteriorly before levering the osteotomy open. Then, use multiple osteotomes to gently pry the osteotomy open from posterior to anterior, keeping the vastus lateralis attached. Retract the fragment anteriorly and remove the prosthesis (Figs. 16 & 17). The ETO can also be performed with an anterolateral approach.

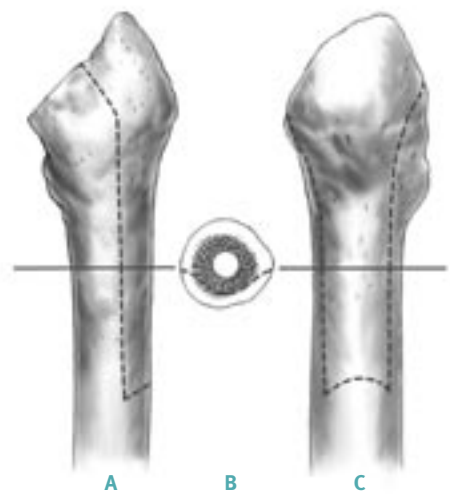


Fig. 16



Fig. 17

A porous-coated implant may still be attached to the proximal femur after the osteotomy has been completed because of bony ingrowth on the medial side. This can be broken down with thin osteotomes or with a Gigli saw. If the distal part of the implant has not been exposed by the osteotomy, then it may be necessary to section the implant at the distal aspect of the osteotomy and use a trephine to remove the distal stem.

Use a burr or a series of broaches to shape the osteotomy fragment to fit the new prosthesis before reattachment. To reattach the fragment, use multiple (usually three or four) double-looped cerclage wires (Fig. 18). Apply any available bone graft to the posterior osteotomy and suture the vastus lateralis back to the septum. If the osteotomy is not stable, use a cortical strut allograft to reinforce it. Abductor laxity can be addressed by shortening the osteotomy fragment and advancing it (Figs. 19 & 20). When testing range of motion and hip stability after reconstruction, be careful to avoid anterior impingement of the osteotomized fragment.



Fig. 18

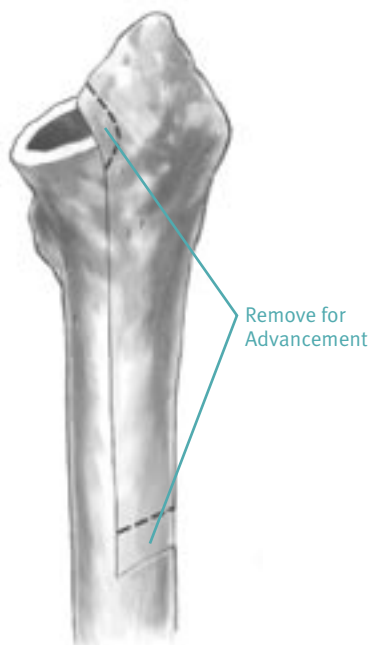


Fig. 19

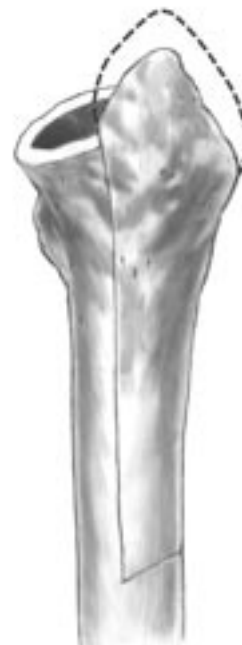

Fig. 20

Determination of Intraoperative Leg Length

Establish landmarks and obtain measurements before dislocation of the hip so that, after reconstruction, a comparison of leg length and femoral shaft offset can be obtained. From this comparison, adjustments can be made to achieve the goals established during preoperative planning.

There are several methods to measure leg length. Use the Zimmer Joint Ruler, or a device/method that is most familiar. Take baseline measurements, then compare adjustments made intraoperatively to the preoperative plan. It is very important to use a reliable method of leg length assessment, particularly in femoral revision surgery, due to the changes in the joint that must be addressed.

Component Removal

At times, various types of trochanteric osteotomies or an extended femoral slot can facilitate femoral component removal. Removal of a well-fixed cemented component is a challenge. It is difficult to extract the implant from the femur while minimizing the risk of fracture and loss of existing bone stock. Avoiding perforation of the femur while removing the old bone cement is also a challenge. Removing a polished or smooth cemented femoral prosthesis is typically easier than removing a device that has a roughened surface. The use of osteotomes proximally helps remove overgrown bone and loosen the bone cement. If the component is difficult to extract, it is helpful to remove as much cement as possible circumferentially to help minimize the chance of fracturing the proximal femur and trochanter.

Many implants have an extraction hole that facilitates the use of an extraction hook with a slaphammer to remove the implant. Identification of the component being removed will allow the appropriate extraction devices to be used.

For femoral implants with modular heads, there are extraction devices available that attach to the implant taper and work with a slaphammer. Some femoral implants have a threaded hole in the shoulder through which an extraction device connector can be mated with a slaphammer. Monoblock devices (fixed femoral head components) can be removed with a looped extraction device and slaphammer.

Once a cemented femoral component is extracted, completely remove the remaining bone cement from the femur. Remove the cement from proximal to distal, including the distal cement plug, if present. This can be accomplished with hand instruments, ultrasound systems, or any other suitable cement removal instruments. In difficult cases, an extended trochanteric osteotomy will provide excellent visualization and access for complete cement removal. If preferred, use the extended femoral slot.

To remove a proximally porous coated femoral implant, carefully disrupt the proximal implant/bone interface and extract the stem using the extraction hole or by securing the taper as mentioned previously. An extended trochanteric osteotomy may facilitate removal of a well-fixed and ingrown proximal porous device. Use high-speed power tools or a Gigli saw to loosen the areas of bone ingrowth anteriorly, posteriorly, medially and laterally.

Removal of an extensively porous coated femoral prosthesis is a more difficult task. An extended trochanteric osteotomy is frequently required. Disrupt the proximal fixation as described above. At times, the implant must be cut at the junction of the proximal body flare and the cylindrical distal stem with a high-speed metal-cutting instrument. After removing the proximal portion of the implant, use a trephine to ream over the top of the distal portion of the stem to break the interface between the implant and bone (Fig. 21).



Fig. 21

Extended Femoral Slot

The extended femoral slot can be used when removal of a cemented implant is difficult. Expose the proximal end of the femur and be sure to remove all soft tissue that might prevent removal of the femoral component. Use thin osteotomes and a femoral extraction device as needed. Under direct vision, remove the proximal cement mantle to the level of the flare of the greater trochanter using cement removing instruments.

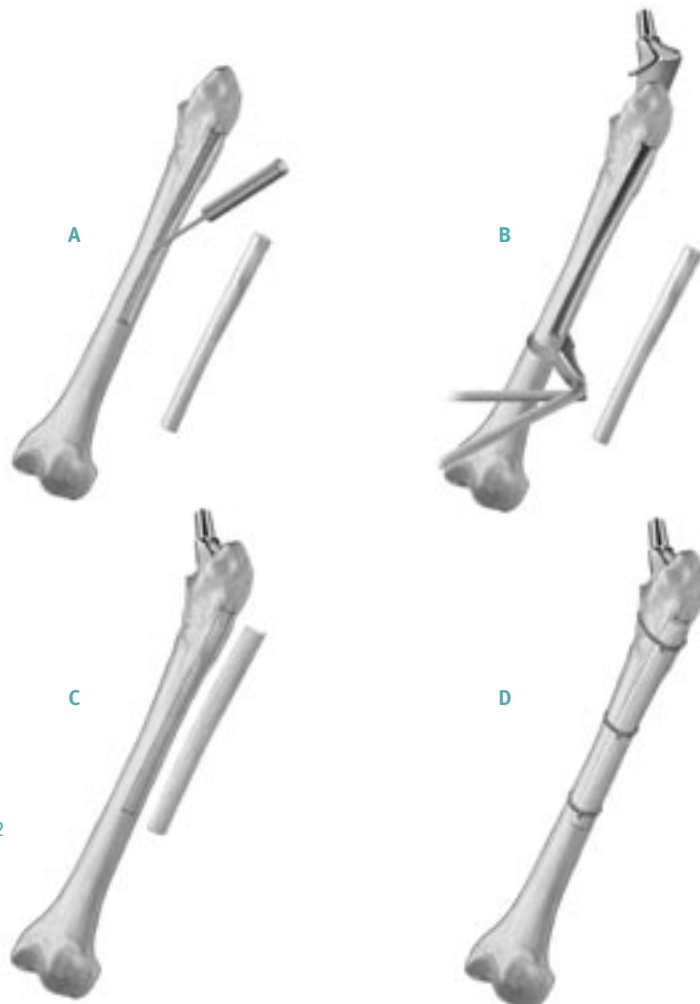


Fig. 22

Expose the femoral shaft below the flare of the greater trochanter by splitting the vastus lateralis. Use a pencil-tipped burr or an oscillating saw to make an extended slot, 1cm-1.5cm wide, in the anterolateral aspect of the femur starting just below the flare of the greater trochanter and continuing to the level of the distal aspect of the cement mantle (Fig. 22). Preoperative measurements are imperative to determine the distal level of the cement mantle. Remove the strip of bone and set it aside to be replaced at the end of the case. Remove the entire cement mantle under direct vision using Hoke osteotomes and other cement removing instruments.

When preparing the proximal femur, it is very important to remove all cancellous bone from the inside of the greater trochanter that might impinge on the shoulder of a long stem prosthesis and increase the risk of fracturing the greater trochanter. Use an osteotome and high speed burr to remove this bone.

The length of the femoral component must be selected to ensure that the distal stem extends beyond the most distal portion of the cortical window by at least two times the diameter of the medullary canal.

Before inserting the final implant, place Verbrugge bone holding forceps just distal to the window to help protect the femur from fracture. After inserting and impacting the stem to its final depth and anteversion, replace the strip of bone that was cut from the slot and reinforce the femoral shaft with a cortical strut graft. Secure the strut graft with multiple *Luque*™ Wires according to the length of the graft.

Osteotomy of the Femoral Neck

In certain situations where sufficient bone is available in the femoral neck, the appropriate size *VerSys* Revision Osteotomy Guide can be used as a reference to determine the level of cut for the selected stem.

Superimpose the *VerSys* Revision Osteotomy Guide on the femur. This guide is a metal replica of the acetate template.

There are two criteria for positioning the guide. First, determine the varus or valgus relationship so the center line of the femoral stem is aligned with the diaphyseal mid-line bisecting the longitudinal axis of the medullary canal. Palpate both the medial and lateral cortices of the femur in the region of the isthmus through the bulk of the vastus lateralis muscle group to determine the distal position of the Osteotomy Guide.

Second, once neutral alignment has been determined, move the template proximally or distally to the correct height, as determined by preoperative planning. The Osteotomy Guides have a linear scale starting at the collar and running distally along the medial edge. This scale is identical to that used preoperatively on the acetate template.

For all sizes of the *VerSys* Beaded FullCoat Revision Hip Prostheses, the center hole marked “REV” should be aligned with the center of rotation of the femoral head. The tip of the greater trochanter should coincide with the mark designated “R” on the lateral edge of the Osteotomy Guide.

The Revision Osteotomy Guide also has two notches that indicate the depth of cut necessary for the +10mm and +20mm calcar build-up stems (see section, Medial Bone Resection for Calcar Stem, for further detail). When implanting a *VerSys* Beaded FullCoat Revision Hip Prostheses do not use the Osteotomy Guides (7890–11, 12, 14, 16, 18) supplied in the *VerSys* Primary General Instrument Set (Fig. 23).

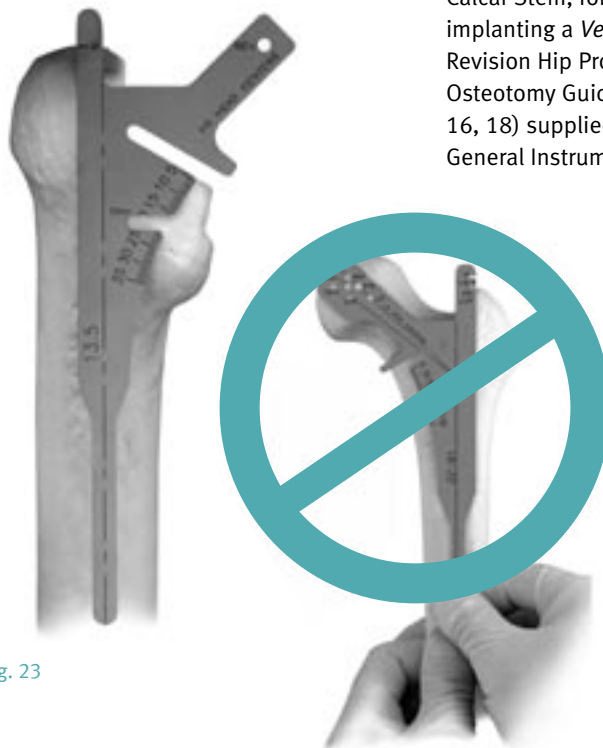

Fig. 23

This alignment of the Osteotomy Guide would be appropriate for most femurs that have a neck shaft angle of 135 degrees. However, if the femur has a neck shaft angle more than or less than 135 degrees, vertical adjustments to the position of the Osteotomy Guide should be made. Use electrocautery to inscribe a line across the femoral neck parallel to the undersurface of the Osteotomy Guide.

Using the inscribed line as a guide, perform the osteotomy of the femoral neck. To prevent possible damage to the greater trochanter, stop the cut as the saw approaches the greater trochanter. Remove the saw and either bring it in from the superior portion of the femoral neck to complete the osteotomy cut, or use an osteotome to finish the cut.

Intramedullary Reaming

Reliable ingrowth with extensively porous coated revision stems requires a scratch fit of the porous coating within the femoral isthmus over a minimum distance of 5cm. If a minimum of 5cm of scratch fit is not possible, other options, including the use of a ZMR[®] Hip System Taper Stem should be considered.

Proper reaming is essential to ensure adequate initial mechanical stability and contact of the ingrowth surface with viable host bone while avoiding fracture, cortical thinning from eccentric reaming, or perforation. With that in mind bone classification will play an important role in determining the final reaming dimension for straight and porous stems. For example, it is not uncommon in Type IIIa and particularly Type IIIb femurs to require a press fit of 0.5mm (underream canal by 0.5mm) for both straight and bowed stems in order to achieve stable fixation. The difficulty in advancing a bowed stem in a press fit situation may be minimized by two factors. The first is the patulous nature of the metaphysis, which provides additional space to accommodate advancement of a bowed stem. Second, many of these difficult revisions are done in conjunction with an extended trochanteric osteotomy, which effectively minimizes the effect of a bowed femur. In most cases it is preferable to start underreaming the diaphysis by 0.5mm and remove additional bone if the prosthesis fails to advance. With that in mind, the following recommendations for canal reaming should be used as guidelines and should be adjusted accordingly based on bone classification, bone quality, and the extent of press fit available in each patient.

The critical first step in preparation for reaming is proper reamer placement. The ideal position is typically the piriformis fossa, although distortion of the anatomy and proximal femoral bone loss, both common in the revision setting, may make it difficult or impossible to identify the piriformis fossa. Failed femoral components often subside into varus. If so, take particular care to ensure that reaming is begun far enough laterally. Avoid placing the pilot hole medially. In addition, any trochanteric overhang will force the reamer into varus. Remove any overhang with a highspeed burr.

Reaming for a Straight Stem

When preparing the distal femoral canal for a straight stem component, the straight IM Reamers (Fig. 24) are recommended; however, if preferred, the flexible reamers can also be used to open the canal prior to using the straight reamer. If an extended femoral slot was used to facilitate removal of the previous implant and bone cement, use the flexible reamers. It is important to ream to the proper depth to assure adequate seating of the implant. The reaming depth should be greater than the preoperatively planned length. This will accommodate any change to the planned components. The straight IM Reamers have depth marks that approximate the length of the prostheses.



Fig. 24

To ream the appropriate depth, advance the reamer at least until the applicable depth mark is just below the medial portion of the osteotomy. Often, an intraoperative A/P lateral radiograph may be taken to check the placement of the straight reamers.

Reamer Mark (Distal to Proximal)	Corresponding Implant Sizes
1st	9,10,11 MidCoat
2nd	12,13,14 MidCoat
3rd	15,16,17,18,19,20 MidCoat, 6-inch FullCoat
4th	8-inch FullCoat
2-inches Past 4th Mark	10-inch Straight FullCoat

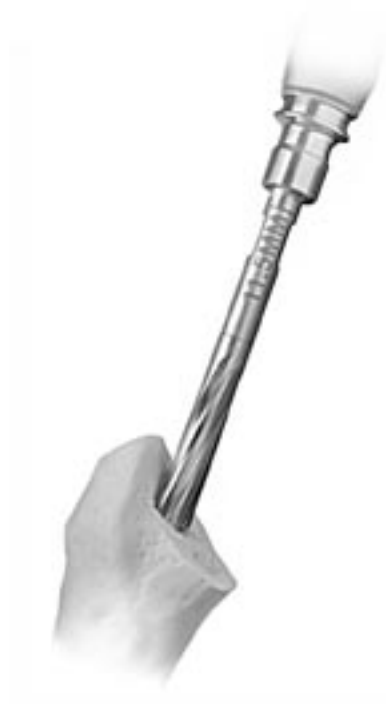

Fig. 25

Initial femoral reaming may be performed by hand using the T-handle. Begin reaming with a straight reamer that is 4mm or 5mm smaller than the anticipated prosthesis size. Continue reaming sequentially in 0.5mm increments, making sure that each reamer is fully advanced to its appropriate depth and centered in the medullary canal (Figs. 25 & 25a). It is important to sense that the direction of the reamer is being controlled by engagement within the isthmus. Avoid varus positioning of the reamers. If the greater trochanter or lateral neck tends to push the reamer medially, use a small conical reamer (Trochanteric Reamer) or a high-speed burr to clear the obstruction and then resume the straight distal reaming. Advance the reamer at least until the applicable depth mark is just below the medial portion of the osteotomy. Often, an intraoperative A/P lateral radiograph may be taken to check the placement of the straight reamers.

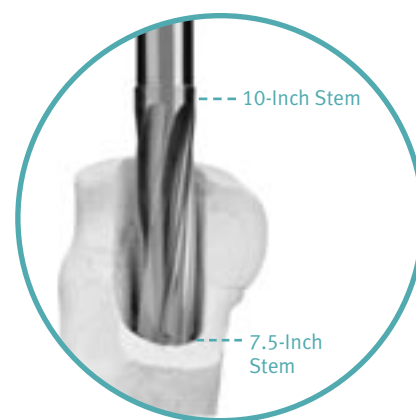


Fig. 25a

Continue progressive hand reaming until initial resistance is felt. Typically, hand reaming should be possible to within 2mm of the diameter of the templated revision stem. If not, repeat the templating process to confirm the optimum component diameter and the desired depth of eventual component seating. Carefully check the lateral radiographic view for the presence of an excessive anterior femoral bow that may be impeding distal passage of the reamer. If such a bow is present, several options exist. First, the proximal anterior femoral endosteum and the posterior endosteum at the level of the isthmus can be relieved with a burr. This will allow the reaming to be redirected more posteriorly. Alternatively, a curved stem may be required and, in the most extreme cases, a corrective osteotomy may be necessary.

If the removed stem was cemented, ensure that all cement has been removed. A retained cement mantle will deflect the side-cutting reamers, making their passage difficult and resulting in eccentric reaming. Use reverse-cutting cement hooks to scrape the endosteum circumferentially to remove any cement.

When revising a failed cementless stem, sclerotic pedestals in the distal canal can also deflect the reamers. Use a long drill to perforate transverse pedestals, then gradually expand them with straight flexible reamers. Eccentric partial pedestals may be very difficult to remove. Generally, use a high-speed burr under fluoroscopic control. If difficulty with hand reaming persists despite the above measures, obtain intraoperative radiographs in both planes with the largest reamer passable to the appropriate depth left in place in order to more clearly define any impediment to further reaming.

Once hand reaming is complete, begin power reaming using sequential reamers in 0.5mm increments. During power reaming, use copious irrigation to facilitate the process by acting as a lubricant, flushing debris, and minimizing thermal necrosis. When preparing the femur for a 7.5-inch (190mm) or 10-inch (250mm) straight stem, ream line-to-line. Underreaming in preparation for a 7.5-inch fully porous-coated straight stem may pose an increased risk of femoral fracture.

Despite optimum manufacturing standards, the diameter of beaded cementless stems can vary by as much as ± 0.4 mm. Furthermore, frequently sharpened reamers may be smaller than their stated size, again in the range of 0.1mm-0.2mm. It is advisable to measure both the final reamer and the actual implant with a Vernier caliper prior to stem impaction.

Reaming for a Bowed Stem

When preparing the femoral canal to accept a bowed stem, flexible reamers must be used because they more closely follow the natural bow of the femur. The *Pressure Sentinel*[®] Intramedullary Reaming System has flexible reamers that result in lower intramedullary pressure levels and lower temperature levels that are at or below those of competitive systems.⁹

Warning: Tactile feedback with these flexible reamers may be different than with straight reamers. Fluoroscopy may be used to monitor the reaming process.

After removing distal cement or sclerotic pedestals, insert a guide wire into the canal, and begin reaming 3mm or 4mm below the anticipated implant size (Fig. 26). Sequentially increase the reamer size by 0.5mm increments, making sure the reamer is fully advanced by passing through the femoral diaphysis. Ream until the desired canal diameter has been achieved.



Fig. 26

Two additional factors must be considered when reaming for a bowed stem. The first is the congruence between the natural bow of the patient's femur and the bow of the revision stem. For straight stems, reaming with a fully fluted rigid reamer creates a cylindrical envelope, in effect, straightening the femoral canal. In contrast, the flexible reamers used to ream for a bowed stem follow the natural bow of the femur. If there is a significant mismatch between the bow of the femur and the stem, one may not be able to seat the implant despite having reamed the canal to the exact diameter of the stem. In fact, it is often necessary to overream the canal by 0.5mm to 1.5mm relative to the stem diameter. The exact amount of overreaming depends on the degree of mismatch.

The second factor to consider is the surgical approach, specifically whether or not an extended trochanteric osteotomy (ETO) has been performed. This has an important bearing on reaming tolerances. The ETO removes the lateral one-third of the proximal femur. Therefore, a bowed stem has slightly enhanced rotational freedom as it passes down the canal, and less overreaming is required.

If an ETO has been performed, begin by reaming to the exact diameter of the revision stem and then attempt to impact the stem. If this fails, ream the canal another 0.5mm. Experience with bowed stems provides an enhanced ability to perceive whether or not complete stem seating will be possible, based on tactile and auditory feedback as the stem is driven in. Progressive overreaming should be undertaken cautiously and in sequential fashion in order to avoid excessive reaming and loss of initial stem stability.

If an ETO has not been performed, and a significant mismatch between the bows is noted in preoperative templating, overream 1.0mm to 1.5mm before attempting stem insertion. If there is no marked mismatch between the bow of the femur and that of the stem, the canal can be reamed between 0.5mm under and 0.5mm over, depending on surgeon preference. Then attempt stem impaction (after appropriate broaching and trial reduction). The stem should advance with each blow of the mallet. If the progress slows dramatically or stops before the stem is two thirds to three-quarters seated, do not continue impaction. Remove the stem and ream an additional 0.5mm and repeat the process.

Rasping

Rasping for an extensively porous coated stem differs both in technique and objective from rasping in primary surgery. In the latter, rasping is intended to crush, impact, and remove cancellous bone. In the revision setting, the metaphysis is typically devoid of cancellous bone and generally presents as a thinned, sclerotic shell of cortical bone. Rasps cannot safely be used to remove this cortical bone, and the rasps are used mainly as sizers to ensure that the smallest metaphyseal size will not impede full seating of the stem size that corresponds to the distal reaming. If the rasp cannot be seated, use a high-speed burr to carefully remove the obstructing bone in the metaphysis and the transitional area between the metaphysis and the isthmus. Pay careful attention to correct anteversion of the femoral stem.

Select the same size rasp that corresponds to the last reamer size that yields initial resistance in the isthmus. Before inserting the rasp into the femur, attach the corresponding size Splined Rasp Alignment Tip to the end of the rasp (Fig. 27) ensuring that the tip is fully engaged with the distal rasp threads (Fig. 27a). The Splined Rasp Alignment Tips are available for sizes 15 to 22.5, and are labeled to correspond with their mating rasp, which are specific to the straight 10-inch stems. The Non-splined Rasp Alignment Tips are available for sizes 12 to 22.5 and are specific to the 7.5-inch straight stems. The purpose of the Splined Rasp Alignment Tips is to centralize the rasp within the reamed canal and minimize malalignment of the rasp which may cause the prosthesis to be positioned in varus or valgus. The diameter of the Splined Rasp Alignment Tips measures 0.5mm less than their labeled size and 1mm less than their labeled size for the Non-splined Rasp Alignment Tips, to maintain appropriate distal clearance. Do not use partially threaded rasp alignment tips (Fig. 28).

Fig. 27



Fig. 27a



Fig. 28



If desired, insert the Rotational Guide through the extraction hole in the rasp, and use it to control rotation when impacting the rasp (Fig. 29). When using the rasp, be sure that it advances with each blow of the mallet. If the rasp can be easily countersunk below the osteotomy line, ream to the next larger, whole size reamer; then progress to the next larger size rasp. Repeat this process until the templated size is achieved.

The final rasp should enable the appropriate implant to fill the femur both proximally and distally. The surgeon should achieve the maximum fill of the opening of the femoral neck and the isthmus of the femur.

After the final rasp has been inserted to a proper level, use the Calcar Planer to plane the femoral neck if necessary to achieve proper fit of the prosthetic collar on the neck. However, in a revision setting, there is often little or no calcar or medial neck to plane. Be aware that there is an increased risk of fracturing osteopenic bone when planing the calcar.

Note: Proximal bone support should be maintained. If femoral preparation has removed bone that would have provided proximal support, bone grafting, or other adjunctive reinforcement procedures will be necessary.

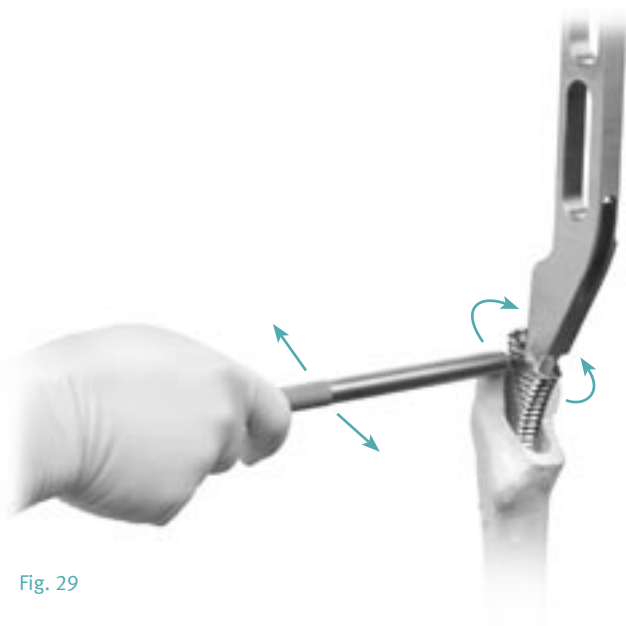


Fig. 29

Medial Bone Resection for Calcar Stem

When preparing for a calcar stem, ream and rasp in the same manner as described above depending on whether a straight or anterior bowed stem will be implanted. Then, after removing the final rasp, use the appropriate size *VerSys* Revision Osteotomy Guide as a reference to determine the level of cut for the build-up of the selected calcar stem.

Superimpose the guide on the proximal femur (Fig. 30). Align the centerline of the guide with the centerline of the femur. Move the guide proximally or distally to the correct height as determined by preoperative planning and intraoperative assessment. The Revision Osteotomy Guides have two notches that indicate the depth of cut necessary for the +10mm and +20mm calcar build-up stems. The size 13.5 Osteotomy Guide has only one notch for a +10mm calcar stem (Fig. 30). These notches are referenced off the tip of the greater trochanter. The guide also has markings to align the +0mm head center for each calcar build-up height. These markings are also referenced off the tip of the greater trochanter. Choose the resection height that preserves the most femoral bone stock. Then mark the level of the cut with a saw or methylene blue.

Cut the medial neck or calcar transversely for about 1cm to accept the implant collar (Figs. 30 & 30a). Then make the longitudinal cut in line with the long axis of the femur and in a plane matching the proper proximal femoral anteversion (Figs. 32 & 32a).

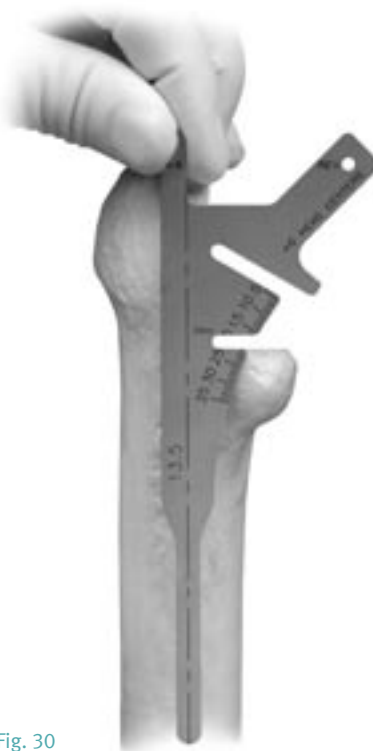

Fig. 30

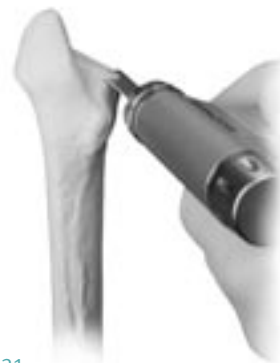

Fig. 31

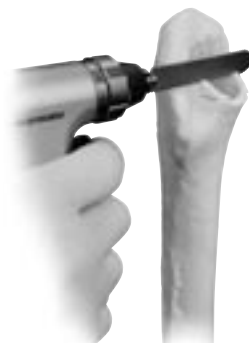

Fig. 31a

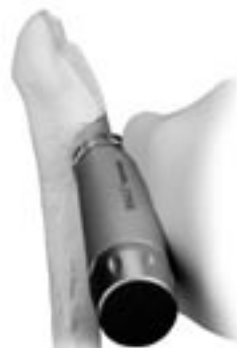

Fig. 32

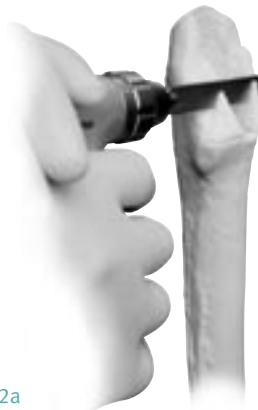

Fig. 32a

Trial Reduction

Before inserting the final prosthesis, perform a trial reduction to assess leg length, abductor muscle tension, joint stability, and range of motion.

All of the 8 and 10-inch Bowed VerSys Beaded FullCoat Revision Stems, as well as the 7.5-inch straight stem, have a corresponding one-piece provisional component. The diameter of the provisional stems measures 1mm less than their labeled size to maintain distal clearance. Based on the instruments used to prepare the femur, choose the appropriate size provisional component. If a 10-inch bowed calcar stem will be used, attach the appropriate size Calcar Block Provisional to the provisional stem as indicated by the arrows on the provisional stem (Fig. 33). Attach the pre-operatively planned Femoral Head Provisional to the trunnion of the stem provisional. If a 10-inch straight stem will be used, assemble an LM Rasp, Cone Collar Provisional, and Splined Rasp Alignment Tip to perform the trial reduction.

When Using a Straight Stem

With the final rasp in place, attach the appropriately sized Cone Collar Provisional and Femoral Head Provisional. If preferred, there is a one-piece Straight Femoral Stem Provisional for each of the 7.5-inch stem sizes. When using the one-piece provisional, remove the rasp and choose the corresponding size 7.5-inch provisional component. When using the one piece provisional, remove the rasp and choose the corresponding size provisional component. If a 7.5-inch straight calcar stem will be used, attach the appropriate size Calcar Block Provisional to the provisional stem as indicated by the arrows on the provisional stem.

If it is difficult to seat the provisional in the femur, there may be a need for additional reaming to remove impinging bone. Assess the fit again with the provisional construct.

Check the leg length and offset of the femur by referencing the lengths measured before dislocating the hip. It is important at this stage to reposition the leg exactly where it was during the first measurement. Adjust the neck length by changing provisional femoral heads to achieve the desired result. For the 26mm, 28mm, 32mm, 36mm, and 40mm femoral heads, the VerSys Hip System has five neck lengths (-3.5, 0, +3.5, +7, +10.5) which provide a total range of 14mm of neck length. When satisfactory leg length, offset, range of motion, and stability have been achieved, dislocate the hip.

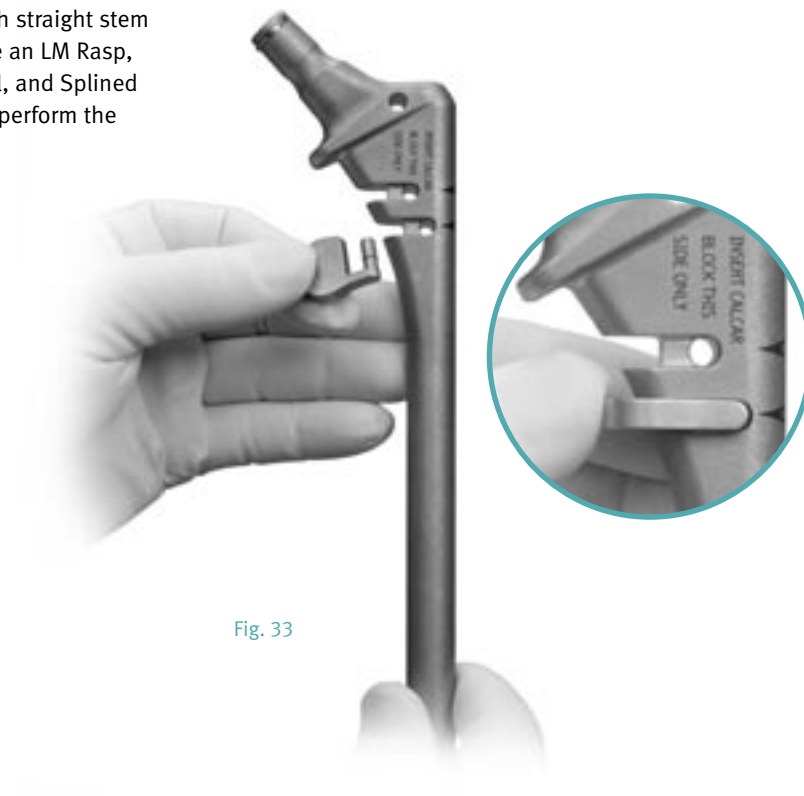


Fig. 33

All provisional stems and rasp faces are etched with a midline mark used to indicate the correct stem orientation in the center of the calcar region of the femur. With electrocautery, use the etched midline to create a medial landmark on the femoral calcar (Fig. 34). This will help guide the rotational position of the final implant; however, the rotation of the final implant does not have to match the mark exactly. Once this landmark has been established, remove the provisional stem or rasp.

For revision situations, the proximal femur may be severely distorted or altogether missing. As a result, it may not be possible to mark a line on the femoral calcar and another method should be used to reference the rotational position of the implant.

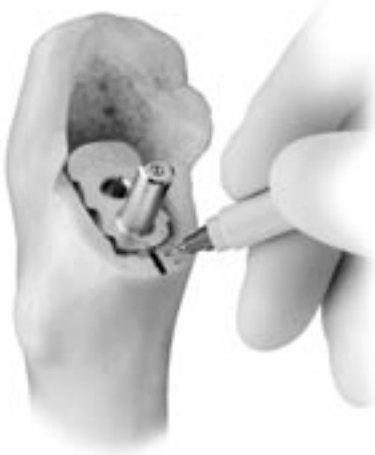

Fig. 34

Implantation

Select the correct size implant. If it is a bowed stem, confirm that it is the appropriate right or left configuration. An etch mark on the flat of the distal stem tip will indicate “Right” or “Left”. If it is a bowed calcar stem, the block height is indicated on the stem tip (Fig. 35).

If proximal femoral bone is very osteopenic, or if any cracks have occurred during rasping, it is recommended to place a *Cable-Ready*® Cable Grip System Cable or wire just below the lesser trochanter before inserting the prosthesis.

Despite optimum manufacturing standards, the diameter of beaded cementless stems can vary by as much as $\pm 0.04\text{mm}$. It is advisable to measure the provisional, splined or smooth rasp tip, and implant with a Vernier caliper prior to stem impaction.



Fig. 35

Stem Insertion

Using the Rotational Guide to control rotation, begin inserting the implant by hand in slight retroversion. After clearing the femoral bow, rotate the implant to a neutral position and continue the insertion until the stem will no longer advance (Fig. 36). Typically, this will be about 5cm-6cm before the collar is even with the osteotomy line. Assess the implant for proper rotational alignment before impacting.



Fig. 36

If desired, attach the Torque Handle to the handle of the Revision Stem Impactor (Fig. 37). To accept the Torque Handle, the impactor handle has four holes located every 90 degrees around the circumference of the handle. Place the Revision Stem Impactor in the implant insertion slot located on the stem shoulder (Fig. 38). This oval slot on the implant is oriented so it will always align with the anterior bow of the stem. Insert the Rotational Guide through the extraction hole on the implant. While an assistant uses the Rotational Guide to control the rotation of the stem, begin to tap the Revision Stem Impactor with a mallet until the prosthesis is seated as desired. Depending on the situation, this revision strategy may not always require the collar or calcar build-up to be seated on the calcar. If the Torque Handle is attached, use caution not to strike it with a mallet. Use the etch mark on the implant to determine the rotation of the stem relative to the mark made on the bone during the trial reduction (Fig. 39). It is not necessary that the two marks be perfectly aligned. They should be used only as guides.



Fig. 37




Fig. 38

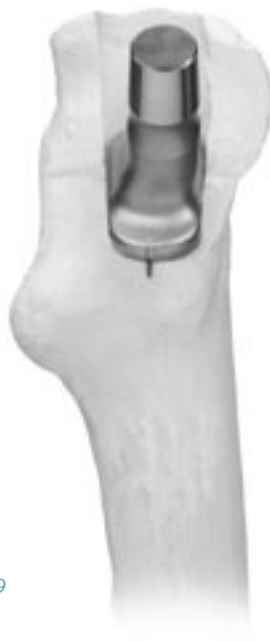

Fig. 39

Optionally, a Rotation Alignment Guide has been included in the product package to aid in stem insertion.

Before impacting the stem, assemble the Rotation Alignment Guide on the implant (Fig. 40). If the pointer on the Alignment Guide points to the landmark on the calcar, adequate rotational alignment will result. If the pointer is pointing to the anterior or posterior side of the landmark, rotate the implant until proper alignment is achieved. Failure to achieve proper rotational alignment prior to impacting the stem may result in femoral fracture or prevent the stem from being fully seated.

If the implant does not advance with each blow of the mallet, stop insertion and remove the component. Then rasp or ream additional bone from the areas that are preventing the insertion and insert the component again.

The rasps and corresponding implants are sized such that a line-to-line press-fit is created proximally. Thus, when the canal is reamed to the size as the final implant (i.e., ream to 15mm and implant a 15mm stem), a line-to-line relationship is achieved between the entire rasp envelope and the implant.

Note: With the implant construct in place, assess the support of the femur and/or adjunctive reinforcement to the proximal region.

Warning: Stem fracture, particularly in heavy, physically active patients, is most likely to occur in a prosthesis that is not supported proximally.

Femoral Head Assembly

Once the implant is fully seated in the femoral canal, place the selected Femoral Head Provisional onto the taper of the implant. Perform a trial reduction to assess joint stability, range of motion, and restoration of leg length and offset.

When the appropriate femoral head implant is confirmed, remove the Femoral Head Provisional. Thoroughly clean and dry the taper on the femoral head component. Then place the selected femoral head on the taper and twist it slightly to secure it. Impact it by striking the Head Impactor with one sharp blow of the Mallet. Test the security of the head fixation by trying to remove it by hand.

Reduce the hip and assess leg length, range of motion, stability, and abductor tension.

Note: Always check that the neck taper and inside taper of the femoral head are clean and dry before impaction. Also, do not impact the femoral head onto the taper before driving the prosthesis down the femoral canal as the femoral head may loosen during impaction of the implant.

Wound Closure

After obtaining hemostasis, insert a *Hemovac*[®] Wound Drainage Device, if desired. Then close the wound in layers.

Postoperative Management

The postoperative management of patients with the *VerSys* Beaded FullCoat Revision Implant is determined by the surgical technique, patient bone quality, patient activity level, fit of the implant, and the surgeon's judgment. Weight bearing after revision surgery typically requires more external support for a longer period due to the nature of the extensive surgery and bone disruption.

Note: Accepted practices of postoperative care should be followed. The patient must be informed and made aware of the limitations of total joint reconstruction and the necessity of limiting weight and physical activity to protect the femoral stem from unnecessary stresses. In patients where proximal support was not achievable, additional risk may be present.



Fig. 40

References

1. Hardings K. The direct lateral approach to the hip joint. *J Bone Joint Surg.* 1982;64B:17-19.
2. Marcy GH, Fletcher RS. Modification of the posterolateral approach to the hip for insertion of a femoral head prosthesis. *J Bone Joint Surg.* 1954;36:142-3.
3. Charnley J, Ferreira A. Transplantation of the greater trochanter in arthroplasty of the hip. *J Bone Joint Surg.* May, 1964;46B:191-197.
4. McGrory BJ, Bal S, Harris WH. Trochanteric Osteotomy for total hip arthroplasty: six variations and indications for their use. *J Am Acad Orthop Surg.* Sept/Oct, 1996;4 (5):258-267.
5. Glassman AH, Engh CA, Bobyn JD. A technique of extensile exposure for total hip arthroplasty. *J Arthroplasty.* 1987;2:11-21.
6. Masri BA, Campbell DG, Garbuz DS, Duncan CP. Seven specialized exposures for revision hip and knee replacement. *The Orthopaedic Clinics of North America.* April, 1998;29 (2):229-240.
7. Younger TI, Bradford MS, Magnus RE, Paprosky WG. Extended proximal femoral osteotomy: a new technique for femoral revision arthroplasty. *J Arthroplasty.* June, 1995;10: 329-338.
8. Aribindi R, Paprosky W, Nourbash P, Kronick J, Barba M. Extended trochanteric osteotomy. *Instructional Course Lectures.* 1999;48:19-26.
9. Agnew SG, Stewart CL, Skinner R, et al. Design influence on pressure and temperature generation from intramedullary reamers: in vitro and in vivo models. Presented at the Orthopaedic Trauma Association Annual Meeting. September 1995; Tamp, FL.

Hamilton WG, Cahsen DV, Ho H, Hopper RH Jr, Engh CA. Extensively Porous-Coated Stems for Femoral Revision: A Choice for All Seasons. *J Arthroplasty.* 2007 Jun; 22 (4 Suppl 1): 106-10. (Front Cover Attribute Statement)



0086

Please refer to the package insert for product information, including contraindications, warnings, and precautionary information.

Contact your Zimmer representative or visit us at www.zimmer.com

