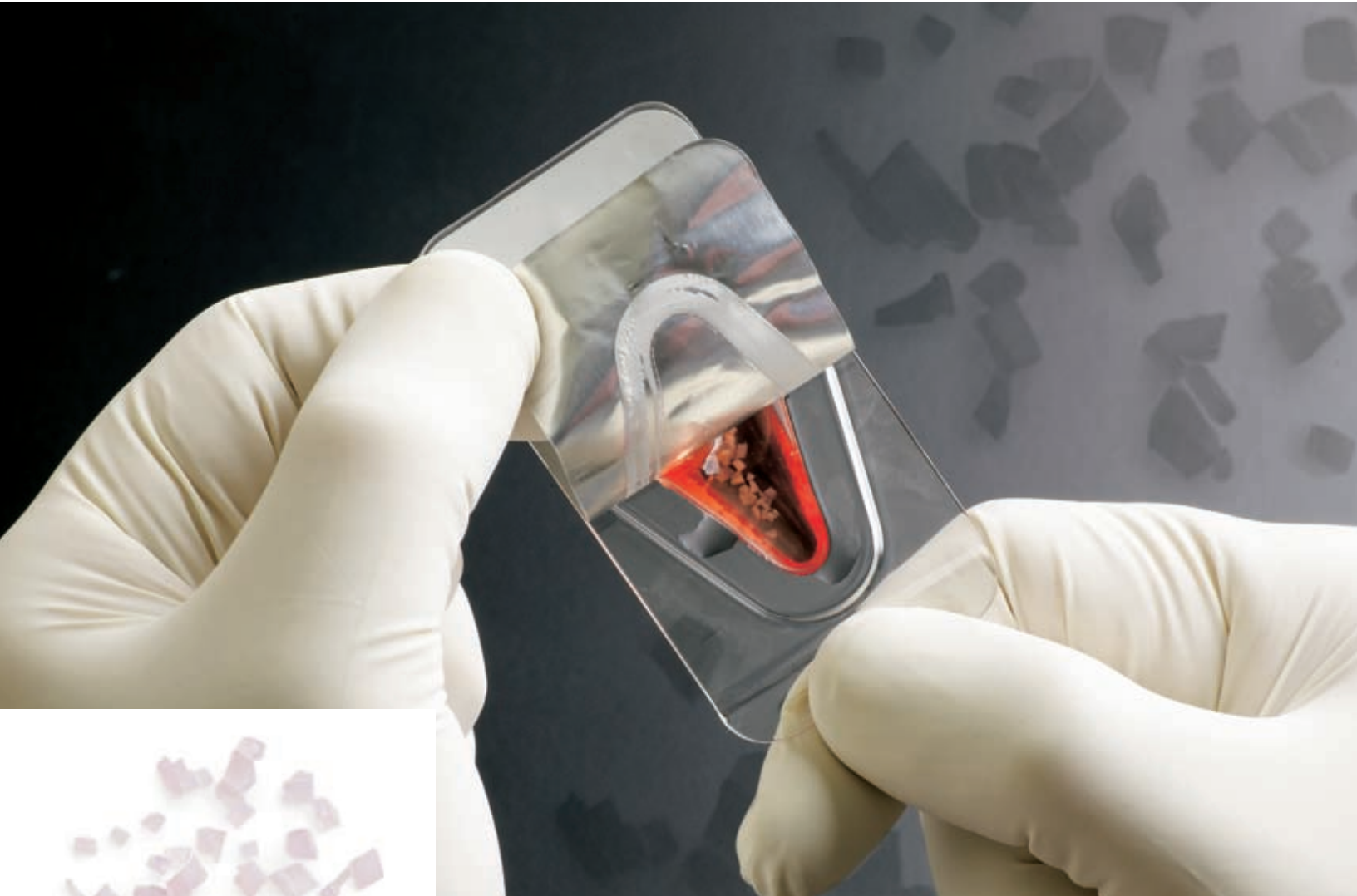



Zimmer®
DeNovo® NT
Natural
Tissue Graft



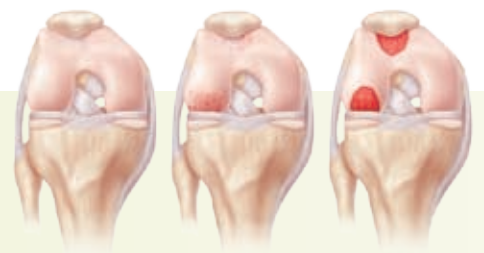Biologic treatment for early intervention and cartilage repair.





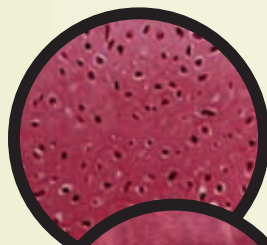
DeNovo NT Graft – Advancing the Science of Cartilage Repair.

DeNovo NT Natural Tissue Graft is a juvenile cartilaginous allograft tissue intended to provide surgeons with an early-intervention option for the repair of articular cartilage in a wide range of anatomic focal cartilage defects. It offers a single-stage procedure with fibrin fixation that eliminates the need for harvesting a periosteal flap. With *DeNovo* NT Graft, Zimmer demonstrates its commitment to leadership in providing surgeons – and their patients – with a complete continuum of joint care.

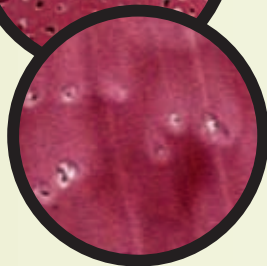

Juvenile Cartilage Tissue

DeNovo NT Graft consists of scaffold-free living articular cartilage, displaying biochemical properties similar to those of articular cartilage found in young, healthy joints.



Juvenile Cartilage
400X



Adult Cartilage
400X

Cartilage Injury and Treatment

- Adult articular cartilage has limited capacity for self-repair.¹
- Untreated focal defects begin a cycle of cartilage breakdown, arthritic degeneration and ultimately, the need for joint replacement.

DeNovo NT Graft offers a simple alternative to focal cartilage defect treatment.



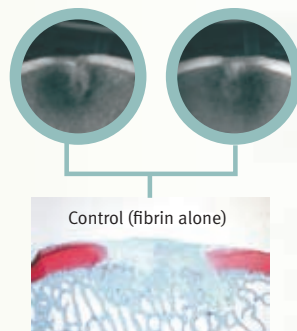
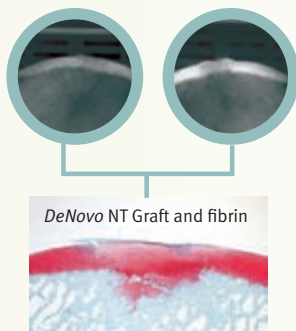
Single-stage Procedure with Fibrin Adhesive

- Simplified surgical technique, unlike ACI.
- No need to harvest and sew a periosteal flap.
- No donor site morbidity, unlike autologous osteochondral transplant.

Pre-Clinical Evidence*

Demonstrated in Equine Trochlea Model at 6 Months Explantation: ²

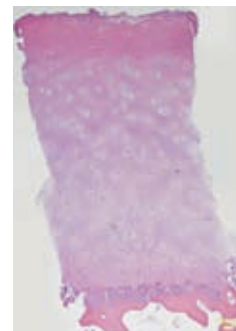
- *DeNovo* NT Graft provided for full-thickness, continuous layer of cartilage repair tissue.
- *DeNovo* NT Graft resulted in minimal subchondral bone resorption.
- Repair tissue integrated into subchondral bone.



Clinical Experience

- Human clinical experience to date includes 2 years of implant history
- *DeNovo* NT Graft has been used to treat focal articular defects in a wide range of anatomical applications, including:
 - Knee (i.e., condyle, trochlea, patella, tibial plateau)
 - Foot and Ankle (i.e., talus, MPJ)
 - Elbow
 - Shoulder (i.e., humeral head, glenoid)
 - Hip (i.e., acetabulum, femoral head)

H&E staining, human biopsy 8 months post-op in 16 year old female trochlear defect.



* Animal Study results are not necessarily predictive of human results.

Comparison of Cartilage Treatment Alternatives

Cartilage Defect Treatment Options	Surgery	Treatment of Defect Area	Tissue Characteristics
DeNovo NT Graft	Single stage	Up to 5cm ² (and greater at surgeon's discretion)	Juvenile hyaline cartilage implanted (up to 13 yrs old)
ACI	Two-stage	Routinely 5-10cm ²	Adult chondrocytes implanted Equivalent clinical outcome to microfracture ³
OATS	Single stage	Limited; 1-3cm ²	NOT juvenile cartilage Donor site morbidity
Microfracture	Single stage	Limited; 1-2cm ²	No tissue implanted Fibrous repair tissue ⁴
Debridement	Single stage	Variable	No tissue implanted
Osteochonral Allograft	Single stage	Typically 5-10cm ²	NOT juvenile cartilage Limited Supply

References:

1. R. Kang, A. Gomoll, S. Nho, T. Pylawka and B. Cole. Outcomes of mechanical debridement and radiofrequency ablation in the treatment of chondral defects: A prospective randomized study. *Journal of Knee Surgery*. 2008; 21: 116-121.
2. Frisbie et al. Data on file at ISTO Technologies, Inc.
3. G. Knutson, J. Drogset, L. Engebretsen, T. Grontvedt, C. Isaksen et al. A randomized trial comparing autologous chondrocyte implantation with microfracture: Findings at five years. *Journal of Bone and Joint Surgery Am*. 2007, 89: 2105-2112.
4. M. Asik, F. Ciftci, C. Sen, M. Erdil and A. Atalar. The microfracture technique for the treatment of full-thickness articular cartilage lesions of the knee: Midterm results. *Arthroscopy: The Journal of Arthroscopic and Related Research*. 2008, 24; 11: 1214-1220.

Contact your Zimmer representative or visit us at www.zimmer.com



+H124975608001001/\$090618R1L095